

Negative staining of the vitreous with the use of vital dyes

Cesare Mariotti¹, Michele Nicolai¹, Simone Donati², Michele Reibaldi³

¹Eye Clinic, Polytechnic University of Marche, Ancona - Italy

²Ophthalmology Clinic, Department of Medicine and Surgery, University of Insubria, Varese - Italy

³Department of Ophthalmology, University of Catania, Catania - Italy

ABSTRACT

Purpose: The vitreous cortex, epiretinal membrane (ERM), and inner limiting membrane (ILM) are transparent tissues and are thus difficult to visualize. Staining these structures can increase the efficiency of a nontraumatic removal.

Methods: The surgeon performs a partial core vitrectomy and induces a posterior vitreous detachment. The vital dye is then injected into the retrohyaloid space in balanced salt solution (BSS). The dyes used are TWIN (Alchimia srl, Padova, Italy), MembraneBlue-Dual (DORC International, Zuidland, the Netherlands), and Doubledyne (Alfa Intes, Casoria, Italy). The surgeon can complete the vitrectomy and gradually aspirate the dye with the probe. Once the vitrectomy is complete, the surgeon can perform the peeling of the ERM without the need to reinject the vital dye over the macula.

Results: The presence of the dye over the macula facilitates visualization of the vitreous cortex by blocking the red reflex and increasing the contrast power of the coaxial light probe during the vitrectomy. This allows a negative coloration of the vitreous because the dye acts by increasing the visibility of the surrounding BSS and not the vitreous itself.

Conclusions: We describe a new chromovitrectomy technique using the same dye to increase the visualization of the vitreous, posterior hyaloid, ERM, and ILM.

Keywords: Chromovitrectomy, Epiretinal membrane, Trypan blue, Vital dyes

Introduction

Accurate removal of the vitreous and complete detachment of the posterior hyaloid membrane is a fundamental surgical step in every vitreoretinal procedure. The vitreous cortex, epiretinal membrane (ERM), and inner limiting membrane (ILM) are transparent tissues, and are thus difficult to visualize. Staining these structures can increase the efficiency of nontraumatic removal. In recent years, several vital dyes such as indocyanine green, trypan blue, brilliant blue, and triamcinolone have been used for chromovitrectomy (1-3).

Triamcinolone acetonide (TA) is used widely to stain vitreous fibrils. The white crystals integrate into the collagen bundles of the vitreous and act as a positive staining of the gel, which makes its visualization and identification easier (4). However, being largely water insoluble, TA can remain longer

in the vitreal cavity after vitrectomy, leading to an elevation of intraocular pressure postoperatively (5).

In addition to pars plana vitrectomy, removal of the ILM may be performed as an adjunct in vitreoretinal surgery in the treatment of macular holes, macular pucker, macular edema, and retinal detachment. The aim of the technique is to improve visualization of the vitreous without staining it directly.

Methods

The surgeon performs a partial core vitrectomy and induces a posterior vitreous detachment by active suction with the vitrectomy probe above the optic disc if vitreopapillary adhesion is present. The vital dye is then injected into the eye through a cannula placed on a syringe through the Weiss ring, if present, into the retrohyaloid space in balanced salt solution (BSS) (Fig. 1). The surgeon can complete the vitrectomy and gradually aspirate the dye with the probe. Once the vitrectomy is complete, the surgeon can perform peeling of the ERM without the need to reinject the vital dye over the macula. The dyes used for this purpose are TWIN (trypan blue 0.18% and blulife 0.03%, Alchimia srl, Padova, Italy), MembraneBlue-Dual (trypan blue 0.15% and Brilliant Blue G 0.025%, DORC International, Zuidland, the Netherlands), and Doubledyne (trypan blue 0.15%, Brilliant Blue G 0.05%, and soluble lutein 2%, Alfa Intes, Casoria, Italy). These dyes contain trypan blue and can stain both ERMs and ILMs.

Accepted: March 19, 2017

Published online: April 13, 2017

Corresponding author:

Michele Nicolai

Clinica Oculistica

Azienda Ospedaliero-Universitaria "Ospedali Riuniti"

via Conca 71

60126 Torrette di Ancona (AN), Italy

michele.nicolai@hotmail.it

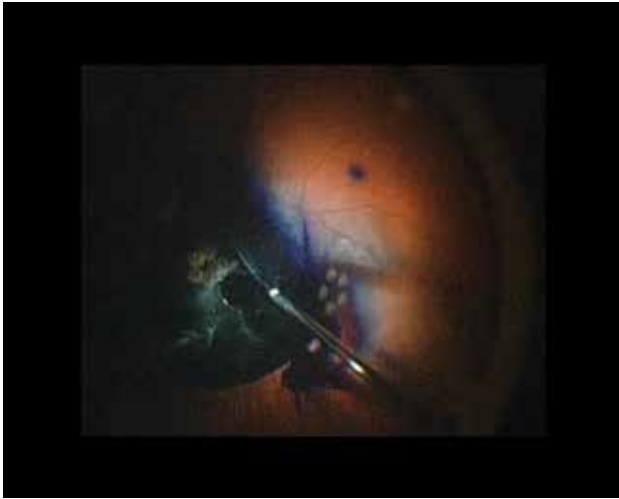


Fig. 1 - The dye enhances the contrast of the posterior hyaloid. Vitreous bundles and Weiss ring are clearly visible during vitrectomy.

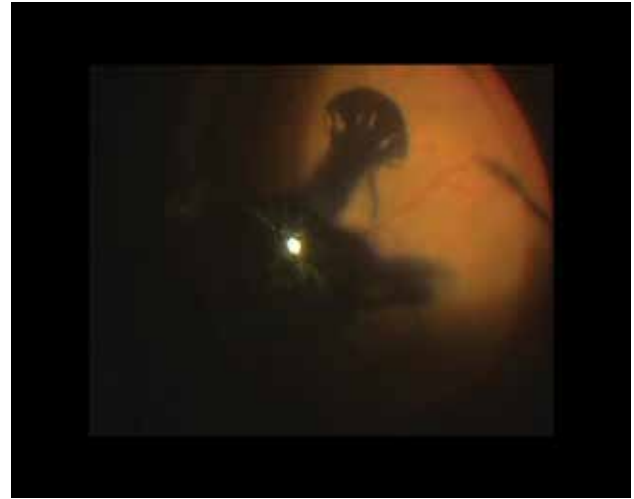

Fig. 2 - The diffusion of the dye highlights the extension of the vitreous detachment towards the periphery.

Results

The dye is water soluble and, because it is denser than BSS, tends to diffuse at the posterior pole behind the vitreous cortex. The presence of the dye over the macula facilitates visualization of the vitreous cortex by blocking the red reflex and increasing the contrast power of the coaxial light probe during the vitrectomy. Blue light reflected by the dye has a shorter wavelength compared to red light and therefore there is higher scattering, resulting in higher contrast and increased visibility of the vitreous fibrils. This allows a negative coloration of the vitreous because the dye acts by increasing the visibility of the surrounding BSS and not directly staining the vitreous itself (see supplementary video 1, available online as supplementary material at www.eur-j-ophthalmol.com).

The presence of the dye at the posterior pole also helps to identify the extension of the vitreous detachment during the vitrectomy because the dye tends to diffuse in the BSS toward the periphery up to the margin of the vitreoretinal adhesion (Fig. 2).

Among the 3 dyes used for this purpose, TWIN has the advantage of being more cohesive as the mixture generates higher intermolecular attraction between the compounds. This property reduces the diffusion of the dye during the vitrectomy and helps the surgeon to avoid a reduction of intraocular visibility as the staining agent tends to remain more confined to the posterior pole in comparison to the other studied dyes.

Discussion

Our technique takes advantage of existing dyes to provide a safe chromovitrectomy by employing the same dye to increase the visualization of different tissues. This represents a new concept of chromovitrectomy with the dye acting as a negative contrast that increases the visibility of surrounding tissue.

The use of the same dye to stain the ERM directly and to highlight the vitreous indirectly may also minimize the risks related to the use of multiple vital dyes.

One of the possible limitations of this technique is that the circulation of the dye can cause a reduction of intraocular

visibility during vitrectomy. To reduce this, the surgeon should keep the tip of the vitrectomy probe in the vitreous gel as much as possible and avoid direct aspiration of the dye at least in the early phase of vitrectomy.

This approach can be used in any macular surgery or in a vitrectomy for retinal detachment when peeling of the ILM is indicated to prevent the risk of causing an ERM (6).

Acknowledgments

The authors thank Laurel T. Mackinnon, PhD, ELS, for English language editing.

Disclosures

Financial support: No financial support was received for this submission.

Conflict of interest: None of the authors has conflict of interest with this submission.

References

1. Farah ME, Maia M, Rodrigues EB. Dyes in ocular surgery: principles for use in chromovitrectomy. *Am J Ophthalmol.* 2009;148(3):332-340.
2. Couch SM, Bakri SJ. Use of triamcinolone during vitrectomy surgery to visualize membranes and vitreous. *Clin Ophthalmol.* 2008;2(4):891-896.
3. Hernández F, Alpizar-Alvarez N, Wu L. Chromovitrectomy: an update *J Ophthalmic Vision Res.* 2014;9(2):251-259.
4. Peyman GA, Cheema R, Conway MD, Fang T. Triamcinolone acetate as an aid to visualization of the vitreous and the posterior hyaloid during pars plana vitrectomy. *Retina.* 2000;20(5):554-555.
5. Sakamoto T, Ishibashi T. Visualizing vitreous in vitrectomy by triamcinolone. *Graefes Arch Clin Exp Ophthalmol.* 2009;247(9):1153-1163.
6. Nam KY, Kim JY. Effect of internal limiting membrane peeling on the development of epiretinal membrane after pars plana vitrectomy for primary rhegmatogenous retinal detachment. *Retina.* 2015;35(5):880-885.